

Effect of Baliospermum Montanum (Danti) for Wound Healing Activity

Please Send
one passport
size photo in
our mail id

Pankaj Singh Niranjn

Designation

Deptt. of Pharmacy,
Bundelkhand University,
Jhansi

Ramji Swarnkar

Assistant Professor,
Deptt. of Pharmacy,
Bundelkhand University,
Jhansi

Suneel Kumar Niranjn

Designation

Deptt. of Pharmacy,
Bundelkhand University,
Jhansi

Fill Above Details

Abstract

Ethanollic extract of the root of baliospermum montanum (euphorbiaceae) was screened for wound healing by excision wound model on wistar rats. The parameter studied were epithelialisation and wound contraction in case of excision wound. The nitrofurazone ointment treated grouped showed a significant reduction in the wound breaking strength when compared to control group in excision type of wound model. The result obtained indicated that baliospermum montanum root extract accelerates the wound healing process by decreasing the surface area of wound and increasing the tensile strength. The histological examination of the granulation tissue of treated group showed increased cross-linking collagen fibers and absence of monocytes.

Keywords: Baliospermum Montanum, Excision Wound.

Introduction

Wound healing involves a highly dynamic integrated series of cellular physiological and biological process which occurs in life organism. Several factors delay or reduce wound healing including bacterial infection, necrotic tissue and interference with blood supply, lymphatic blockage and diabetes mellitus(1). Baliospermum montanum contain alkaloids, glycosides, flavonoids, roots yield five new phorboloysters belonging to diterpine, hydrocarbons, tiglione skeleton viz inotain, baliospermin. The root are acrid, termogenic, purgative, anti-inflammatory, anoidyne, digestive, anthelmentic, diuretic, diaphoretic, rubefacient, febrifuge and tonic. They are useful in anasarca, dropsy, flatulence, constipation, haemorrhoids, leprosy, skin diseases, anameia, leucoderma etc.

Material and Method

Animals

Wistar rats of either sex used for the study of the crude extracts institutional animal ethics committee have approved the project (registration number-BU/PHARM/IAEC/09/2003). The animals were kept at $27 \pm 2^{\circ}\text{C}$, relative humidity 56% and light and dark cycles of 10 and 14 hrs respectively for 1 week before and during experiments. Animal were provided with standard diet and water. The food was withdrawn 18 and 24 hr before the start of the experiment. All the experiment were performed in the morning according to the current guidelines of CPCSEA.

Plant Collection and Preparation of Extract

The roots of Baliospermum montanum were collected from barabanki district (U.P.) in month of sepetember 2009, and authentication of plant material was done by Dr. Tariq hussain (NBRI, LUCKNOW) with assession number 97306. Roots were shade dried coarsely powdered and extract were prepared by maceration method. The extract was filtered and vacuum dried.

Acute Toxicity Study Ald_{50}

The acute toxicity study for ethanollic extract of Baliospermum montanum roots was performed using wistar rats. The animals were fasted overnight prior to the experiment and maintained under standard condition. The extract was administered orally in increasing dosage and found safe up to a dose of 200mg/kg. The fixed dose (OECD guideline NO.420) method of CPCSEA was adopted for toxicity studies.

Wound Healing Activity

Adults wistar rats of either sex weighing 160-200 gm were used for the study. The effect of the extract was evaluating on excision models in rats. Nitrofurazone ointment (0.2% w/w) was used as a standard drug for comparing the wound healing potential of the extract in different animal model. The wound healing activity was assessed by the rate of period of epithelialisation and skin breaking strength. Histological study of granulation tissue was carried out to know the extract of collagen formation in the wound tissue.

Excision Wound Model

The wound side was prepared following the excision wound model. Three group of six animals each were used. The rats were anaesthetized prior to and during infection of the experimental wound. The surgical interventions were carried out under sterile condition during diethyl ether. Wound of 400 sq. mm on dorsal thoracic was made .animals were closely observed for any infection and those which showed sign of infection were separated and exuded from the study and replaced. The animals were observed wound closure at 0,5,10 and 15th day and for period of epithelialisation.

Histopathological Studies

The healing tissue obtain on the 15th day from all three groups of animals of the excision wound model were proceed for histological studies. The amount of collagen was quantified using vangeison stain.

Statical Analysis

Tha data are expressed as the mean ± S.E.M. The difference among means has been analyzed by one-way ANOVA. A value of p< 0.05 was considered as statically significant.

Result

Preliminary Phytochemical Screening

Phytochemical investigation of root extract showed the presence of alkaloids, glycosides, flavonoids, and diterpines.

Acute toxicity study

Before the study of wound healing activity, preliminary toxicity studies of the treated extract were carried out. The treated extract did not cause any mortality when administered up to a dose of 2000 mg/kg body weight orally.

Excision wound model

Percentage closure of original wound area was calculated at different times interval. The measurement of 5th and 10th day showed that the percentage closure of the original excision wound area was found to be 51.55 and 78.80 (standard ointment treated group), 47.33 and 76.42 (BM root extract). The treated extract significantly promoted wound closure compared to control on 15th day. The extent of percentage wound closure was 98.00 (standard ointment treated group), 97.35 (BM root ethanolic extract).

Table -1
Effect of Extract on Healing of Excision Wound Model

Group	Wound Area (mm ²) Post Wounding Days				Period of Epithialisation
	0 th	5 th	15 th	0 th	
Control	406.6 ± 5.30 (0.0)	312.82 ± 14.05 (22.0)	186.5 ± 09.2 (53.5)	82.82 ± 8.8 (79.29)	24.09 ± 0.20
Standard	402.6 ± 5.21 (0.0)	194.5 ± 17.30 (51.5)	84.5 ± 7.03 (78.8)	08.04 ± 0.83 (98.00)	17.08 ± 0.70
Extract Treated	403.3 ± 3.61 (0.0)	210.65 ± 5.86 (47.33)	94.30 ± 7.05 (76.42)	10.6 ± 4.50 (97.35)	19.17 ± 0.42

Values are the mean ± SEM, one way ANOVA, n = 6, Values Showing Percentage Closure of Original Excision Wound Ar

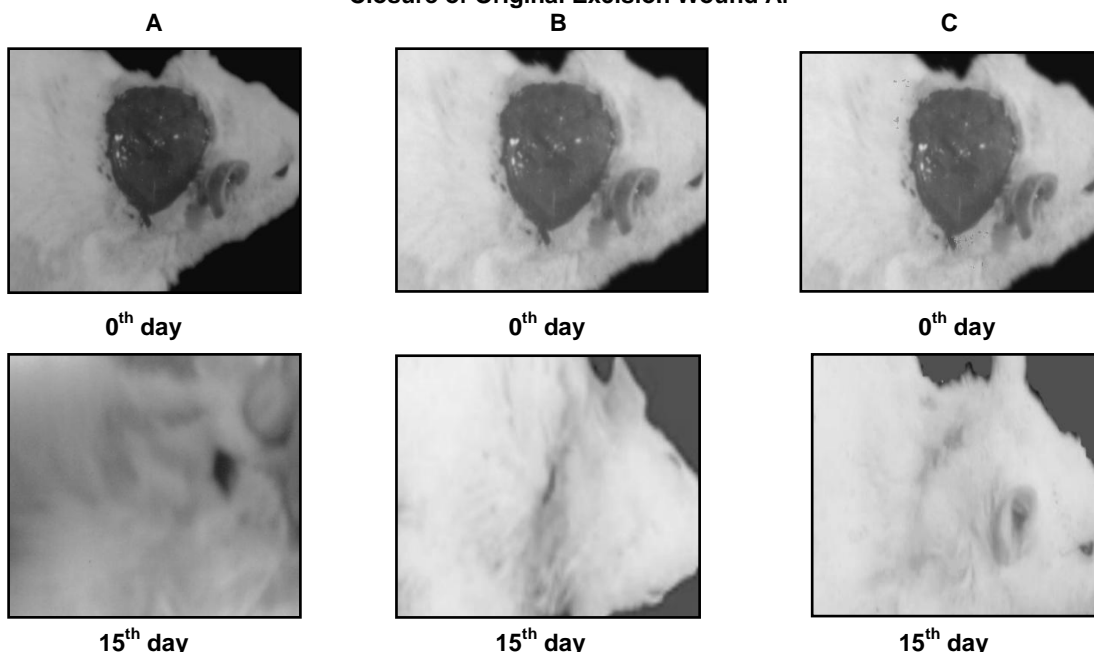


Figure 1. Comparison of Wound Site by Excision Wound Model in Control (A), Standard Ointment Treated Group (B) and Extract Treated Group (C)




Figure 2. Histopathological Characteristics of Healed Tissue Treatment with Control, Standard and Test Groups. 2 A: Granulation Tissue of Control Group Animal Showing with Less Collagen and More Macrophages (Vangeison Stain). 2 B: Granulation Tissue of Nitrofurazone Ointment Treated Group Animal Showing Moderate Deposition Collagen (Vangeison Stain). 2 C: Granulation Tissue of Extract Treated Group Animal Showing More Collagen and Less Macrophages (Vangeison Stain)

Discussion

The repair of wounds involves different phases including contraction, formation of epithelialisation and fibrosis. Comparison of the epithelialisation between the standard and with extract is very necessary part of the study. Topical application of ethanolic extract at wound side in excision wound model that produce significant ($p < 0.001$) wound healing activity. Treated surface show an increased rate of wound contraction leading to faster healing as confirmed by the stabilization of the fibers facilitating wound healing. The wound breaking strength is determined by the rate of collagen synthesis and more so, by the maturation process where there is covalent binding of collagen fibers through inter and intra-molecular cross linking. The BM root extract treated with rats increase wound contraction, it would have increasing contractile properties of myofibroblast and its number. The extract was promoting epithelialisation either by enhancing the viability of epithelial cells.

For conclusion, The observation and result obtained in this study indicated that the BM root extract significantly stimulated wound contraction. The breaking strength of the treated excision wound

increased in the treated groups compared with the control group.

References

- Bertram G.K, In; Basic and clinical pharmacology; MC Graw Hill publishers; 1990; 7:854.
- Charde M.S, Fulze S.V, Sahurwar P, Dorle A.K: Study at wound healing of Darvhighrita, Indian Drug 40: 115-118.
- Sapna M., Neelesh M., Goel R.K. et al.: Anc. Sci. Life 27, 14 (2007).
- Khandelwal K.R.: Practical Pharmacognosy, 14th ed., p. 149, Nirali Prakashan, Pune 2005.
- Nagappa, A.N., Binu C.: Fitoterapia 72, 503 (2001).
- Ehrlich H.P., Hunt T.K.: Ann. Surg. 167, 324 (1968).
- Hukkeri V.I., Nagathan C.V., Karadi R.V. et al.: Indian J. Pharm. Sci. 68, 124 (2006).
- Lee K.H.: J. Pharm. Sci. 57, 1042 (1968).
- Nayak S., Rao S.G., Murthy K.D. et al.: Indian J. Exp. Biol. 41(6), 645 (2003).
- Keuman R.E., Logan M.A.: J. Biochem. 186, 549 (1972).
- Gabbaiani G., Harschel B.J., Ryan G.B. J. Exp. Med. 135, 719 (1976).